



PRESENTING CLINICAL SIGNS

DATE History: Coughing. Radiographs show tracheal and bronchial collapse, as well as suspect left-sided cardiomegaly.

7/20/23

ECHOCARDIOGRAPHIC FINDINGS

2D, M-mode, and Doppler study.

PERFORMED BY:

Val Shumskaya

Left atrial size is normal. The mitral valve leaflets are mildly thickened, and a mild jet of mitral regurgitation is present. Left ventricular internal dimensions are normal. Left ventricular systolic function is hyperdynamic. The aorta and aortic valve are normal. Right atrial and right ventricular dimensions are normal. The tricuspid valve appears normal, though trace tricuspid regurgitation is present. The pulmonary artery and pulmonic valve are normal. No pericardial effusion or cardiac masses are seen.

INTERPRETED BY

Keith Blass, DVM,
MS, DACVIM
(Cardiology)

LA - 28.4 mm
LVIDd - 28.0 mm
LVIDs - 12.4 mm
FS - 55.7%
RA - 20.3 mm
LVOT - 1.21 m/s
RVOT - 1.18 m/s

PATIENT

Lotlot Dealday

ASSESSMENT/RECOMMENDATIONS

Degenerative mitral valve disease

SPECIES

Canine

This examination demonstrates mild regurgitation of blood across Lotlot's mitral valve resulting from degenerative valve disease. The hemodynamic effects of the regurgitation also appear to be mild, as Lotlot does not have secondary dilation of either of his left heart chambers, and his left ventricular systolic function is well-preserved. As such, Lotlot's mitral valve disease appears to be well-compensated, and it does not appear to be contributing to his cough.

BREED

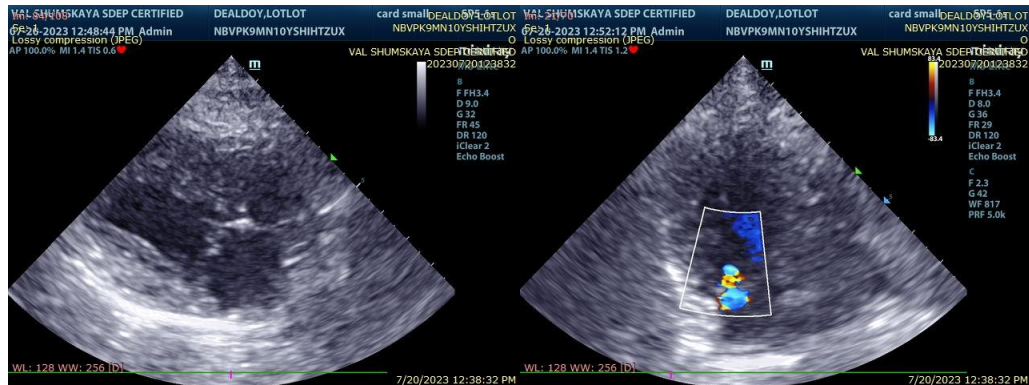
Shih Tzu Mix

No therapy is recommended at this stage of disease.

SEX

A recheck echocardiogram is recommended in 6 months to monitor for disease progression.

MN



AGE

WEIGHT

20.6 lb

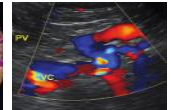
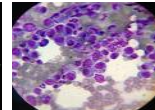
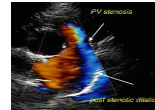
HOSPITAL NAME

New Bridge VP

REFERRING VET

Dr. Glennon

The information and recommendations provided are based on the images presented by the referring veterinarian. No evaluation can be communicated regarding pathology that was not



visible in the image/video clips provided.

DATE Thank you for this referral. If the clinical or image interpretation does not parallel your findings or if I can be of any further assistance please contact me.

7/20/23

PERFORMED BY: Keith Blass, DVM, MS, DACVIM (Cardiology)
KeithBlass@gmail.com
631-804-5754

Val Shumskaya

INTERPRETED BY

Keith Blass, DVM,
MS, DACVIM
(Cardiology)

PATIENT

Lotlot Dealday

SPECIES

Canine

BREED

Shih Tzu Mix

SEX

MN

AGE

WEIGHT

20.6 lb

HOSPITAL NAME

New Bridge VP

REFERRING VET

Dr. Glennon